

Host Genes and HIV Infection: Implications and Applications

Disease emergence often involves the introduction of a familiar microbial agent into a novel ecologic niche or the evolution of a previously unrecognized microorganism in what had ostensibly been a stable environment. So accustomed are we to emergence brought on by changes in an agent or its environment that we overlook effects of the third force of causality—the host. The easy justification for our relative indifference to the contributions of the host has been that host characteristics, especially those under genetic regulation, have less potential for rapid, epidemiologically significant evolution; moreover, the genetic mechanisms of host response have been too poorly elucidated to permit rational manipulation.

The emergence of human immunodeficiency virus (HIV), however, has been different. HIV has “emerged” so masterfully by exploiting fundamental vulnerabilities in the immune system of primates that contributions of host immunity cannot be ignored. The virus has apparently evolved from its simian cousins toward a form that is extraordinarily well adapted to humans in several ways: 1) it rapidly replicates, ensuring high mutation rates within an individual host; 2) it is readily transmissible from person to person in the absence of an animal vector; and 3) because it is not invariably lethal before the age span for most human reproduction, evolutionary pressure toward radical change, attenuation, or disappearance from the population is not strong. The enormous epidemiologic implications of these basic facts have become obvious during the decade and a half of our struggle against the virus. We cannot control it by manipulating its macroenvironment as we might a parasite carried by a vector or waterborne virus. Interrupting local transmission by setting up psychosocial or mechanical barriers has limited potential. Despite the recent highly encouraging advances in antiretroviral therapy, direct and complete pharmacologic or immunologic eradication of the virus worldwide is still an untenable prospect. So we have little choice but to search for biologic strategies that reliably interdict the host-virus relationship; to accomplish that will require insight into the fundamental mechanisms of that interaction—knowledge at the level of viral and host genetics. Indeed, modulating genetically

determined features of the immune response to the virus may represent the best hope for its ultimate conquest. Recent breakthroughs have accelerated the accumulation of the knowledge necessary to accomplish that aim. In this issue of *Emerging Infectious Diseases*, the review of current information by McNicholl and colleagues about the genetics of virus-host interaction concentrates on the recently described variations in genes encoding the human β -chemokine receptors, appropriately providing perspectives from both laboratory and public health sciences.

The quest to identify immunogenetic determinants of the host-virus interaction in HIV infection actually began with studies of the human major histocompatibility complex (HLA) soon after the AIDS epidemic was recognized, but in the past 2 years molecular technology has been focused on promising loci in the chemokine receptor gene systems, as well as in HLA. The importance of polymorphic variants of these host genes in determining whether the infection occurs and how rapidly it proceeds has been established.

The extreme polymorphism and other related properties of HLA have made it more difficult than expected to demonstrate the full influence of products of these genes on the initiation and progression of HIV infection; however, current work on HLA is slowly confirming that expectation, which is reasonably based on 25 years of research on the role of antigen-presenting genes in a whole range of autoimmune, inflammatory, and infectious processes. In contrast, β -chemokines and the genetically mediated variation in their receptors were recognized only recently, but the initial observations and numerous confirmatory reports of their involvement in HIV infection have been compelling, and there is undoubtedly more to come.

The most important consequence of these recent discoveries has been to foster an aggressive academic and industrial enterprise aimed at developing a safe, clinically beneficial immunomodulation of β -chemokines and their receptors in both infected and uninfected persons. The relative simplicity of the gene system, the frequency of the apparently protective variant (i.e., the 32bp deletion) of CCR5, and the seemingly nonessential nature of either the wild or mutant form of the receptor for normal immune function have suggested that emulation of the unreceptive mutant state (e.g., by saturating

the normal receptor with a specific high affinity chemokinelike antibody) might interrupt viral penetration and replication. The implication here is clear. If antibodies to the normally functioning CCR5 can block viral attachment and prevent infection of the cell most critical to propagation of the agent without collateral damage to vital host immune function, a vaccine capable of inducing those antibodies without serious adverse effects could represent an adjunct to the current anti-retroviral therapeutic agents and a major breakthrough toward a primary preventive strategy not dependent on changing personal behavior. The optimism and publicity that often accompany this kind of success must be tempered with caution: the strategy depends heavily on whether HIV can circumvent this hurdle by utilizing CXCR4 or other alternative pathways of entry into cells.

However, even if the promise of preventive and therapeutic intervention based on chemokine receptor manipulation is not soon fulfilled, another tangible benefit inherent in the discovery of factors like the receptor variants and HLA polymorphisms should not be overlooked. These genetic factors, however amenable or resistant to clinical manipulation they may prove to be, have true prognostic value and therefore offer a clear, immediate opportunity to refine our ongoing evaluations of other promising therapeutic or preventive measures. Consider the randomized trial of a new chemotherapeutic agent, intentionally designed to compare its average efficacy in all trial participants with the average efficacy of the conventional agent. Because HIV-1-infected persons who are heterozygous for the CCR5-deletion progress more slowly than those who carry only the wild type, stratifying the study population according to the presence or absence of the deletion, either during randomization or during analysis, should clarify whether the benefit of the experimental regimen in study participants who also carry the more favorable genetic trait is additive or even synergistic. Moreover, in clinical settings other than randomized trials, the additional information about receptor deletion status may be essential to analyzing the

effects of interventions under evaluation or to customizing patient care.

The possibility that the genotype information might be used to refine the observations from current clinical research and to individualize the management of HIV-infected or even uninfected persons has also raised questions about whether typing more routinely might be appropriate. Although the concept of identifying a predisposing factor and modifying recommendations for treatment or prophylaxis accordingly is well established in the management of infectious diseases, screening for a particular genetic trait is not. So another implication of the research on host genetics in HIV infection is that it will probably draw health professionals into many of the same opportunities, obligations, and ultimately controversies that already surround the discovery of genes predisposing to cancer or chronic metabolic diseases like hemochromatosis. What may distinguish genetic screening in the context of infectious diseases from the rest, and even impose greater urgency for decisions about genetic testing, is that carriers of a genetic trait conferring relatively high risk may be readily capable of taking explicit precautions to avoid exposure to an identifiable etiologic agent. In short, in some situations the payoff may be more immediate.

The discovery of host genes that exert major influence on the acquisition and progression of HIV infection has radically altered our thinking about the pathogenesis of retroviral infection. The prognostic value of these genetic factors should be incorporated into the assessment of interventions to control the infection. The intense effort under way to translate knowledge of these human genetic traits into clinical benefit for HIV-infected and uninfected persons reflects a new rationale for research on emerging infectious diseases: consider the host, as well as the agent and the environment.

Richard A. Kaslow

University of Alabama at Birmingham
Birmingham, Alabama, USA

Controversies in the Management of Cysticercosis

Cysticercosis, an infection caused by larvae of the pork tapeworm *Taenia solium* in human tissues, is a common cause of neurologic disease in most non-Muslim developing countries, where it accounts for more than one-third of adult-onset epilepsy cases (1). Cysticercosis is increasingly diagnosed in patients in industrialized nations; persons who have never left the United States as well as visitors to disease-endemic regions are at risk. Traditionally considered an exotic disease, this infection now accounts for up to 2% of neurologic/neurosurgical admissions in southern California (2) and more than 1,000 cases per year in the United States (3). Further away from disease-endemic regions, an outbreak of cysticercosis among orthodox Jews living in New York City was reported after food was contaminated with *T. solium* eggs by immigrant cooks infected with the pork tapeworm (4); these carriers may have been completely unaware of their infections. Neurocysticercosis has been reported in AIDS patients, but immuno-suppression does not appear to increase the incidence of this infection. Once cysticercosis is diagnosed, treatment may be necessary, but optimal therapy and particularly the role of cestocidal drugs is controversial. In this commentary, we discuss current options in the treatment of established cysticercosis.

The clinical and pathologic features of neurocysticercosis vary, depending on the inflammatory response around cysticerci, their number, size, and location. The presence of viable, living cysticerci in the central nervous system usually does not cause symptoms (5). In contrast, inflammation around degenerating cysticerci may have severe consequences, including focal encephalitis, edema, and vasculitis. The most frequent symptom is epilepsy. However, neurocysticercosis can cause a wide variety of clinical syndromes—from chronic meningitis and cranial nerve palsies to spinal infarction and symptoms due to either a mass effect or, particularly in racemose disease, raised intracranial pressure. Such variable clinical features necessitate further investigations to make a diagnosis before treatment.

The diagnosis may be made by excision biopsy of subcutaneous cysticerci, which are found in 4% to 25% of patients with neurocysticercosis (the percentages are higher in Asia than in Latin

America). However, radiologic and serologic tests are usually required for diagnosis unless biopsy of a central nervous system lesion is possible. Computed tomography visualizes living cysticerci as hypodense lesions not enhanced with intravenous contrast; a small, hyperdense scolex may be observed within a living cyst (6). Degenerating cysticerci which are more often symptomatic are isodense or hyperdense, and edematous inflammation around them usually causes ring or nodular enhancement by intravenous contrast (5). Magnetic resonance imaging provides detailed images of living and degenerating cysticerci, as seen in a heavily infected patient (Figure), but may not detect calcified, destroyed cysticerci (3). An immunoblot diagnostic test on serum has been shown to have greater than 98% sensitivity and specificity (7). However, in patients with single ring-enhancing lesions, sensitivity falls to 60% to 80%. Sensitivity is also reduced if cerebrospinal fluid rather than serum immunoblot is used.

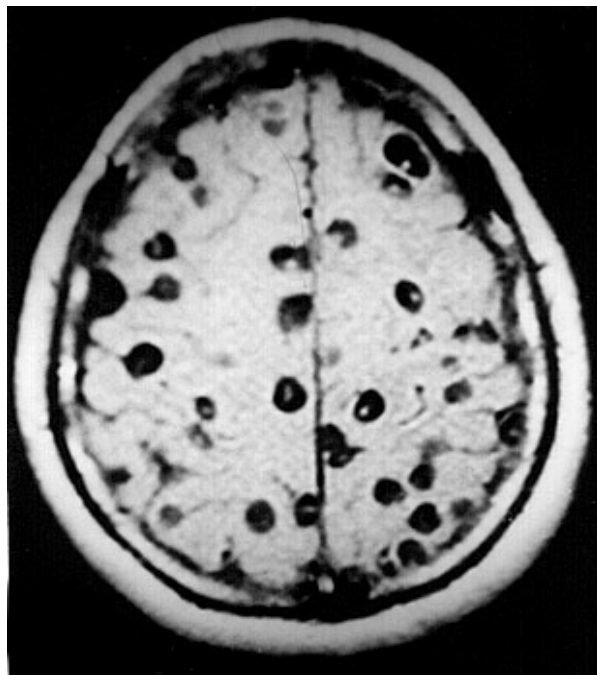


Figure. Magnetic resonance image of a patient with neurocysticercosis demonstrating multiple cysticerci within the brain.

The treatment of established neurocysticercosis is controversial and probably depends on the associated inflammatory reaction as well as clinical and pathologic features. Symptomatic

therapy with conventional anticonvulsant drugs is indicated to control epilepsy. Symptoms often result from self-limiting inflammation around a degenerating cysticercus (3,5). Raised intracranial pressure caused by this local reaction usually responds to oral corticosteroids. Steroids have been given chronically in occasional cases of persistent intracranial inflammation. Surgery also has a role: a ventriculoperitoneal shunt relieves obstructive hydrocephalus, although shunt blockage is common when the cerebrospinal fluid protein is elevated. Because inflammation associated with medical therapy may threaten vision, surgery has been used to excise intraocular cysticerci. Asymptomatic subcutaneous or intramuscular cysticerci do not require treatment.

Cestocidal therapy with praziquantel (50 mg/kg/day tid orally for 14 days) or albendazole (15 mg/kg orally tid/bid for 8 to 15 days) accelerates radiologic disappearance of viable intracranial cysticerci. Albendazole may have slightly greater efficacy and is generally less expensive than praziquantel. Cestocidal treatment combined with symptomatic care is associated with a good clinical outcome (8,9). However, these nonrandomized trials were not optimally controlled, and a similarly benign clinical course has been described after symptomatic treatment alone in both adults (5) and children (10). Furthermore, randomized placebo controlled trials with selected patients have shown no clinical (11) or radiologic (12,13) benefit from the addition of cestocidal therapy to symptomatic care. A problem with cestocidal therapy is that it causes influx of inflammatory cells around cysticerci, which is often associated with transient clinical deterioration (8). Rarely, this may be fatal in heavy infections, despite administration of corticosteroids, a common practice to minimize adverse effects (6). Although coadministering corticosteroids reduces blood levels of praziquantel and increases those of albendazole, these effects do not appear to be relevant clinically. Therefore, the immunologic basis has yet to be determined for the inflammation around cysts when they die or are killed by cestocidal treatment (14).

Although recommendations cannot yet be definitive, available evidence suggests that viable, intact cysticerci that cause epilepsy or other symptoms can be treated with cestocidal therapy, especially if they are causing mass effect. If cestocidal treatment is instituted, there is no

reason to avoid the use of steroids. These should always be administered before cestocidal therapy is given to patients with multiple viable intracranial cysticerci because the sudden and simultaneous death of these parasites would otherwise cause inflammation, which can be fatal. In contrast, when untreated patients have neurologic symptoms and radiologic evidence of inflammation around a degenerating cysticercus, the parasite has probably already died, and cestocidal therapy is unlikely to be of benefit. In such cases, an expectant policy is reasonable: symptomatic therapy alone for 6 to 12 weeks, unless the patient's condition worsens. A repeat computed tomography scan then usually shows reduction in size or disappearance of a degenerating cysticercus (12,13,15). If improvement has not occurred, then empirical cestocidal chemotherapy may be considered, and possible alternative diagnoses such as tuberculosis should be entertained. Intracranial calcifications and lesions that show ring enhancement on neuroimaging are not living parasites and probably do not warrant cestocidal therapy.

This approach to cestocidal therapy is controversial, and the results of at least one ongoing, double-blind, randomized placebo-controlled trial are keenly awaited. Even when the value of cestocidal therapy is firmly established or refuted, new antiinflammatory treatments will require therapeutic approaches to be reevaluated. A greater understanding of the pathogenesis of this condition is a prerequisite to developing effective therapy to control inflammation around degenerating cysticerci.

Acknowledgments

The ongoing collaboration between the authors is funded in part by the Wellcome Trust of the United Kingdom, STD4 project PL 950004 from the European Commission, and grant number 1-U01 A135894-01 from the National Institutes of Health, USA.

Carlton Evans,* Hector H. Garcia,†† Robert H. Gilman,‡§ and Jon S. Friedland¶¹

*University of Cambridge Clinical School, Cambridge, United Kingdom; †Instituto de Ciencias Neurológicas, Lima, Peru;

‡Universidad Peruana Cayetano Heredia, Lima, Peru; §Johns Hopkins University School of Hygiene and Public Health, Baltimore, USA; and ¶Royal Postgraduate Medical School, Hammersmith Hospital, London, United Kingdom

¹Corresponding author

¹Corresponding author

References

1. Garcia HH, Gilman R, Martinez M, Tsang VCW, Pilcher JB, Herrera G et al. Cysticercosis as a major cause of epilepsy in Peru. *Lancet* 1993;341:197-200.
2. McCormick GF. Cysticercosis: review of 230 patients. *Bulletin of Clinical Neurosciences* 1985; 50:76-101.
3. Shandera WX, White AC, Chen JC, Diaz P, Armstrong R. Neurocysticercosis in Houston, Texas. *Medicine* 1994; 73:37-52.
4. Schantz PM, Moore AC, Munoz JL, Hartman BJ, Schaefer JA, Aron AM, et al. Neurocysticercosis in an orthodox Jewish community in New York City. *N Engl J Med* 1992; 327:692-5.
5. Kramer LD, Locke GE, Byrd SE, Daryabagi J. Cerebral cysticercosis: documentation of natural history with CT. *Radiology* 1989; 171:459-62.
6. Wadia N, Desai S, Bhatt M. Disseminated cysticercosis: new observations, including CT scan findings and experience with treatment by praziquantel. *Brain* 1988; 111:597-614.
7. Tsang VCW, Garcia HH. Immunoblot diagnostic test (EITB) for *Taenia solium* cysticercosis and its contribution to the definition of this under-recognized but serious public health problem. In: Garcia HH, Martinez SM (editors). *Teniasis/ Cisticercosis por T. solium*. Lima: Ed. Universo; 1996. p. 259-69.
8. Sotelo J, Escobedo F, Rodriguez J, Torres B, Rubio F. Therapy of parenchymal brain cysticercosis with praziquantel. *N Eng J Med* 1984; 310:1001-7.
9. Vasquez V, Sotelo J. The course of seizures after treatment for cerebral cysticercosis. *N Engl J Med* 1992; 327:696-702.
10. Mitchell WG, Crawford TO. Intraparenchymal cerebral cysticercosis in children: diagnosis and treatment. *Pediatrics* 1988; 82:76-82.
11. Carpio A, Santillan F, Leon P, Flores C, Hauser A. Is the course of neurocysticercosis modified by treatment with antihelminthic agents? *Arch Intern Med* 1995; 155:1982-8.
12. Padma MV, Behari M, Misra NK, Ahuja GK. Albendazole in neurocysticercosis. *Neurology* 1994; 44:1344-6.
13. Padma MV, Behari M, Misra NK, Ahuja GK. Albendazole in single CT ring lesions in epilepsy. *Natl Med J India* 1995; 8:255-8.
14. Evans C, Gonzalez AE, Gilman RH, et al. Cysticercosis: immunology and immunotherapy. In: Rose FC (editor). *Recent advances in tropical neurology*. Amsterdam: Elsevier; 1996. p. 155-64.
15. Singhal BS, Ladiwala U. Neurocysticercosis in India. In: Rose FC (editor). *Recent advances in tropical neurology*. Amsterdam: Elsevier; 1996. p. 99-109.